

## CHRONIC PANCREATITIS AND PANCREATIC CANCER

L. B. Lazebnik<sup>1</sup>, L. V. Vinokurova<sup>1</sup>, N. I. Yashina<sup>2</sup>, E. V. Bystrovskaya<sup>1</sup>, D. S. Bordin<sup>1</sup>, E. A. Dubtsova<sup>1</sup>, Y. N. Orlova<sup>1</sup>

<sup>1</sup>*Central Research Institute of Gastroenterology,*

<sup>2</sup>*Institute of Surgery n. a. A. V. Vishnevsky of the Ministry of Health and Social Development, Moscow, Russia*

**Key words:** chronic pancreatitis, precancer, pancreatic cancer, computed tomography, endoscopic ultrasonography

In most developed countries, cancer of the pancreas (pancreatic) is one of the leading places in the morbidity and mortality of cancer of the digestive system. The peak incidence occurs in 60-80 years. In men, prostate cancer is 4, 5 women leading cause of cancer death. Risk factors for pancreatic cancer are eating large amounts of fat, smoking, chronic pancreatitis, diabetes. If the role of diabetes as a risk factor for prostate cancer is estimated by various researchers are not clear, the value of chronic pancreatitis (CP) is generally recognized. In CP risk of prostate cancer is higher than in the population at 20 times, and in hereditary - 60 times. If the role of diabetes as a risk factor for prostate cancer is estimated by various researchers are not clear, the value of chronic pancreatitis (CP) is generally recognized. In CP risk of prostate cancer is higher than in the population at 20 times, and in hereditary - 60 times.

CP Diagnostics is based on an assessment of clinical, data visualization techniques RV detection of exo- and endocrine pancreatic insufficiency. The most important methods of differential diagnosis of CP and pancreatic cancer are imaging techniques: computed tomography (CT), magnetic resonance imaging (MRI), transabdominal ultrasonography (TUS) and endosonography (EUS). It should be emphasized that each of these separately performed studies may not be sufficient for correct diagnosis. Timely diagnosis of pancreatic neoplasia and to determine the indications for surgical treatment allows a comprehensive assessment of clinical and

anamnestic data, results of ray, endoscopic and morphological studies, supplementing and clarifying each other. The study of the properties of pancreatic perfusion by CT to evaluate the degree of morphological changes of cancer. It is known that CP alcoholic etiology, especially with a primary lesion of the pancreas head, often "pretend" cancer of the pancreas. Improve the quality of diagnosis allows EUS with fine-needle biopsy and morphological verification of diagnosis. In addition, the identification of mutations in KRAS in the material obtained by fine-needle biopsy of pancreatic tissue was significantly associated with a malignant process.

Inadequate assessment of pathology may contribute to the choice of the wrong tactics of the patient: the dynamic monitoring of patients who have shown surgical treatment for undiagnosed malignancy, or, on the contrary, enhanced pancreatic-duodenal resection in CP. The patient has prostate cancer the most important in the preoperative determine the potential for resection (resectability), or obvious signs of unresectable tumor that forms the basis of selection of the optimal treatment strategy. Therefore, the combined use of CT and EUS is able to improve the quality of diagnosis, to increase the number of radical and avoid repeated surgical procedures, as well as reduce the algorithm for the examination of patients with diseases of the pancreas.

**Aim of research:** determination of the diagnostic value of computerized tomography and endosonography in the evaluation of changes in chronic pancreatitis and pancreatic cancer.

**Materials and methods.**

The study is based on the results of a survey of patients at the Institute of Surgery. Vishnevsky (computed tomography) and Central Research Institute of Gastroenterology (EUS). The study involved 375 patients, including 179 with a diagnosis of CP and 146 - with cancer localized in the pancreatic head (mean age  $52,45 \pm 7,85$  years). To evaluate the normal CT anatomy of the prostate and

surrounding structures in the study also included 50 control patients without lesions of the gastrointestinal tract.

Table 1

**The distribution of patients with cancer (adenocarcinoma), pancreatic head by type of surgery**

Type of operation	Number of patients (n=146)
Pancreatoduodenectomy	89
Gepatikoeyunoanastomoz	38
- In combination with Gastroenteroanastomosis	6
Gastrojejunostomy	5
Thoracoscopic splahnncsimpatektomia	6
Enteroenteroanastomosis	1
Diagnostic laparotomy	7

89 of 146 patients with pancreatic cancer is made pancreatoduodenal resection, histological examination was performed operating preparations, including remote pancreatoduodenal complex, dissected lymph nodes, retroperitoneal fat and paravazal nerve plexus. In 32 patients operated on the verification of the diagnosis of adenocarcinoma of the pancreatic head was based on the basis of histological studies of organ and lymph node metastases. The nature of operations is shown in Table 1.

CT was performed on a helical CT scanner TOMOSCAN SR 7000 (Philips) in the mode of spiral CT and multislice computed tomography "BRILLIANSE-64» (Philips). Endoscopic ultrasound study was carried out on the unit Fujinon EQ-530UT. Fine-needle biopsy was carried out in diagnostically difficult cases where CT and EUS data were insufficient to determine the guiding further treatment.

Statistical data processing was performed using a statistical software package «CSS / STATISTICA».

**Results of research.**

The clinical picture of the disease in CP and pancreatic head cancer were similar. Jaundice, weight loss, pain in the upper abdomen, lumbar region, exocrine and / or endocrine insufficiency, acute attacks of pancreatitis were observed in both cases. In analyzing the results in abdominal CT control group indicated that the degree of contrast uptake tissue cancer at a young age has a minimum density spread, while in the elderly this scatter extremely emphasized and it depends on the number of inclusions of fat tissue cancer, severity of atherosclerotic lesions and, consequently, the degree of tissue fibrosis. The decrease in the native phase-contrast perfusion reflects cancer properties, increasing the density of glands in the delayed phase of the study indicate the presence of fibrosis in its structure (Table 2).

Table 2

**The degree of accumulation of contrast agents pancreatic parenchyma in various age categories of the control group**

Age	Phases of research (ед.Н)			
	native	arterial	venous	delayed
20–29 years	42± 1,8	120±4,3	88±2,2	70±2,4
30–39 years	42±2,5	117±5,4	83±3,6	68±1,7
40–49 years	40±1,9	113±3,7	80±5,1	68±2,1
50–59 years	36±5,1	100±6,2	86±,7	76±6,3
60–75 years	33±4,3	96±8,3	85±7,2	80±9,5

A special form of chronic pancreatitis is autoimmune pancreatitis (AIP). The classical CT sign of AIP with diffuse disease cancer is thickening in a sausage shape, a weak accumulation of contrast medium with the presence of hypodense rim on the periphery of the gland. Diffuse form of AIP should be differentiated from acute edematous pancreatitis. A distinctive feature is that the AIP hypodense rim around the distal relatively uniform width not exceeding 57 mm, acute pancreatitis tissue infiltration parapancreatic uneven and more pronounced blurring of contours cancer. In a later phase of acute pancreatitis in the formation of fluid accumulation in the

structure are found sequesters consisting of gland tissue and areas of fat, and when attached infection infiltrate seen in the structure of air bubbles.

Local lesions in AIP are hypodense or izodense area, located mainly in the pancreatic head. They can imitate tumor. The diagnosis in these cases is determined on the basis of detectable hypodense rim of the "halo" around the periphery of prostate tissue, increase plasma levels of immunoglobulins (IgG4), as well as according to histology: marked diffuse or focal lymphoplasmacytic infiltration around the pancreatic ducts, periductal fibrosis, and ductal destruction obliterative phlebitis.

Diagnosis of focal forms of AIP on the basis of CT alone is difficult because when contrast lesion slowly increased density and differ little from the CT signs of cancer. Lack of visualization of the main pancreatic duct (UPF) also creates a diagnostic difficulties in this form of AIP and requires differential diagnosis of emerging Postnecrotic cysts and cystic tumor.

One of the observations in a patient with AIP CT was found to tumor formation in the body of cancer, and in the preoperative diagnosis of pancreatic cancer was specified. The formation was considered unresectable due to massive adhesions and the involvement of the great vessels, and therefore performed decompression of the biliary tract with gepaticoeunoanastomoza. In the subsequent dynamic CT after a course of hormone replacement therapy there was a reduction in the formation of the body of the pancreas. In 2 cases there was a decrease, followed by the disappearance of signs of inflammation in the background of the conservative steroid therapy.

According to EUS in AIP also there is either diffuse enlargement of the prostate (diffuse form) or patchy education, simulating a tumor (focal form). Echostruktura RV hypoechoic with hyperechoic foci of fibrosis and periductal hypoechoic areas located parenchyma relevant lymphoplasmacytic infiltration. The walls of the BPU are thickened, irregularly narrowed lumen periductal foci of fibrosis and lymphoplasmacytic infiltration. In all cases, we observed were detected thickening of

the wall of the common bile duct and the enlargement of the lymph nodes (Fig. 1 a, b, c, d).

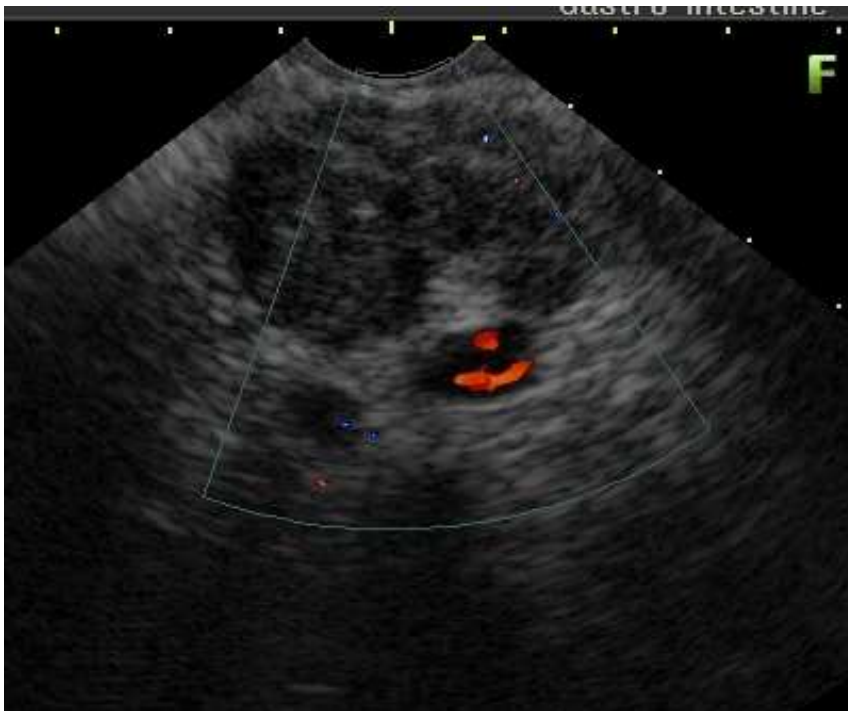

Fig. 1a

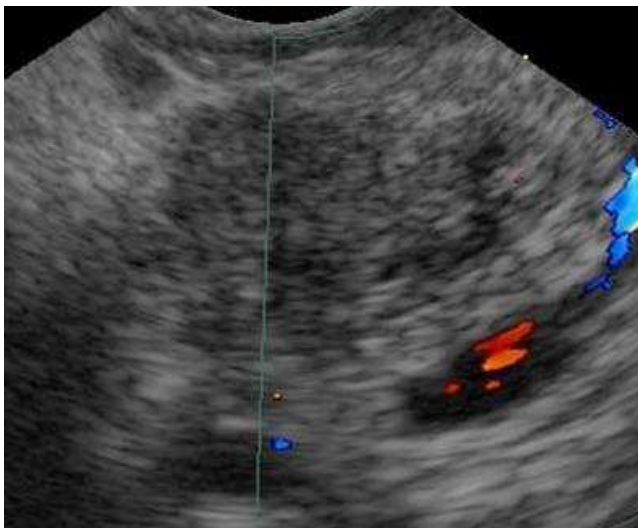


Fig. 1b

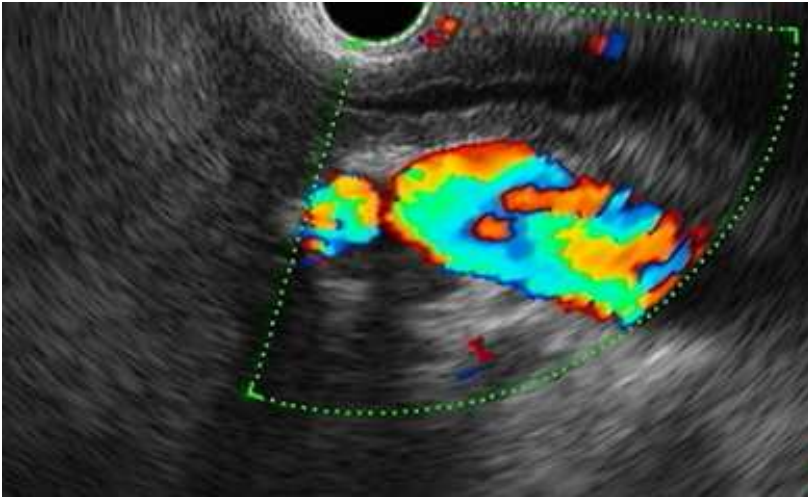


Fig. 1c

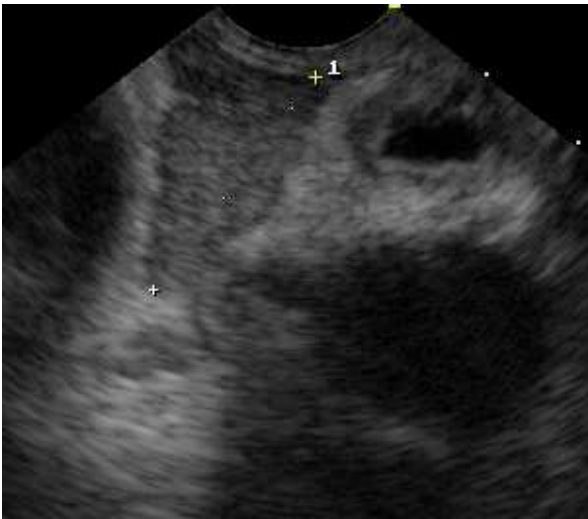

Fig. 1d

Fig. 1. Ultrasound picture of autoimmune pancreatitis

- a) Focal pancreatic formation simulating tumor (focal form). Echostructure of the pancreas is hypoechoic, with hyperechoic foci of fibrosis and periductally located hypoechoic areas of parenchyma. Periductally located hypoechoic areas of the pancreatic parenchyma
- b) Uneven narrowing of the main pancreatic duct with wall thickening
- c) Common bile duct's wall thickening
- d) Enlargement of regional lymph nodes

Fine-needle puncture with aspiration biopsy and cytology often uninformative due to the random nature of the distribution centers of infiltration. Therefore the result of the biopsy specimen in obtaining prostate tissue without surgery, may be false-negative. Therefore, in cases of suspected AIP role of cytology prostate tissue to a greater extent is the removal of tumor than in the proof of the AIP.

Diagnosis of cancer (adenocarcinoma), pancreatic head and differential diagnosis with CP on CT also has some difficulties.

The main and primary adenocarcinoma of the head is a sign of the presence of the bulk of education in its structure. Of the 146 patients examined, the formation was determined in 119 (81.5%) patients. Tumor size ranged from 1.7 cm to 15 cm (mean  $4,3 \pm 1,8$  cm). In the group of non-resectable tumors the size of education were on average  $4,9 \pm 1,0$  cm. In 27 (18.4%) patients, diagnosis was based on indirect signs of the tumor. As such can serve as a rounded shape of the head, combined with the increasing size. When the native study found no major differences in the densities of tissue and prostate tumors, the size of which does not exceed 3 cm in the arterial phase of the study the accumulation of contrast agent in the tumor was weak. Average density values of education were  $55 \pm 9$  ed.N. A 17 (11.6%) patients in this phase of the study was determined by the periphery formation hypercontrast rim. Reduction in the density in the central parts of the tumor, corresponding to the zone of secondary fibrosis (desmoplastic reaction) was observed in 67 (45.8%) patients.

There was a marked dependence of the CT picture of cancer of the pancreatic head of the expansion of GLP-induced tumor invasion. Germination GLP varying severity was observed in 102 (69.8%) patients with ductal adenocarcinoma. In the arterial phase of the study indicated a proportional reduction in contrast uptake gland by increasing the diameter of the pancreatic duct. Received contrast material in edematous tissue slow and weak. The mean values of the density of the gland tissue in the arterial phase were  $69 \pm 8$  ed.N. On the background of the "carcinogenic" pancreatitis tumor in the arterial phase seen much worse. Its indirect signs include



biliary and pancreatic hypertension with block-level education. With a small increase GLP (4 mm) detected in 15 (10.2%) patients atrophic changes in the distal cancers were minimal. If you extend the main pancreatic duct to 47 mm, was observed in 54 (36.9%) cases, atrophic changes in the tissue were moderate and were expressed in its reduction. The mean values of the density of the gland tissue accounted for  $92 \pm 7$  ed.N, which is below that of the control group (115 ed.N). 32 patients (21.9%) patients duct diameter was 721 mm, densities cancer and tumor were not different from each other and synchronously changed during all phases of contrast.

In the group of patients with evidence of "cancer-causing pancreatitis" without germination pancreatic duct after maximize the arterial phase of the study the density of the gland tissue in venous phase was reduced to  $85 \pm 5$  ed.N. The concentration of the contrast agent in the tumor tissue was increased, the tumor became almost izoden relatively gland tissue. In the research phase is delayed in the absence of pancreatic hypertension observed further enhancing tumor accumulation of contrast medium, which was better seen on the background of lowering its density gland. The data presented in Table. 3, indicate that the expansion and improvement of GLP tissue swelling worsens visualization of formation.

Table 3

**Comparative evaluation of performance and density of the tumor tissue cancer depends on the extension of the main pancreatic duct in the different phases of contrast enhancement (n=41)**

Structural elements	Investigation phases, density (unit.H)			
	native	arterial	venous	delayed
Tumor	35±5	46±6	64±6	72±9
The unchanged breast tissue in the presence of a tumor without extension of GLP (n = 10)	38±3	94±9	87±8	78±6
The unchanged in the presence of breast tissue and tumor expansion GLP	34±8	62±8	72±7	76±4

(n = 31)				
----------	--	--	--	--

The presence of concomitant cystic lesion in the head with adenocarcinoma was observed in 7 (4.7%) patients. Its formation was due to the blocking of the lateral tumor pancreatic duct and its extension to form a retention cyst. All cysts were located at the periphery of the tumor and head cancers. When tumor size of 23 cm in 11 (57.8%) cases had been an increase of bile ducts. In 7 patients with biliary hypertension has been the only sign of the presence of a tumor. In 10 (13.1%) patients, an indirect sign of malignant lesions were metastases in the liver. In 3 (2.9%) of patients with localized generalization of tumor in the pancreatic head was found ascites.

*Differential diagnosis of CP and pancreatic head cancer*

In 16 (8.9%) patients with histologically verified CP at RT was wrongly diagnosed with pancreatic head cancer. Local form of CP options that mimic the CT features of the tumor are shown in Table. 4. Thus, in all cases CPs can be identified education in the pancreatic head, imitating a tumor. In this indirect signs (biliary and pancreatic hypertension) are nonspecific and are not observed in all cases.

Table 4

**The combination of CT features in different types of local forms of chronic pancreatitis**

Variants of chronic pancreatitis n=16	CT- signs			
	Pseudo-formation in head	Biliar hypertension	Pancreatic hypertension	Enlarged lymph glands
Immature cysts (n=7)	+	-	+	+
Autoimmune pancreatitis (n=4)	+	+	+ -	-
Segment pancreatitis (n=2)	+	+ -	-	-
Duodenal dystrophy (n=1)	+	-	+ -	-
Parapancreatic infiltrant(n=2)	+	-	-	+

In the early phase of the formation of cysts Postnecrotic its content has semifluid consistency and higher density (2025ed.N) compared with the already formed cysts (515ed.N). The relatively high density of the content and structure of the inhomogeneity of the emerging Postnecrotic cysts can imitate tumor. In the follow notes or her recourse or due to autolytic processes and deposition of particulate matter in the blood and pus, there are characteristic features of the cyst followed by the formation of false capsule. The criterion for the differential diagnosis of emerging cysts and cancer is no reduction in the zone of reduced density in the delayed phase of the study cyst (detritus).

The inflammatory process of the gland tissue segment (segmental pancreatitis) may also be taken for the swelling head. The modified portion of the breast at CT is better seen in the arterial phase of the study, when the density gradient is most expressed. In the venous and delayed phase of increased density of the modified and unmodified tissue is reduced. When the retrospective assessment of CT images, attention is drawn to the triangular shape of the lot with the inflammation sufficiently clear outline, without departing from the head gland, which subsequently helps in the correct diagnosis.

The presence of parapancreatic infiltration indicates the absence of pancreatic hypertension in large sizes of education, availability of the complete Postnecrotic cysts in the distal gland swelling and formation of adipose tissue around.

When Histomorphological study, 12 (14.1%) was found micropreparations pronounced ductal epithelial dysplasia. In 15 (8.7%) cases of atypical marked changes in the background of the expressed cellular destruction, which were regarded as a microscopic picture of the ductal adenocarcinoma «in situ». With dynamic CT study can be seen the emergence of soft tissue component in developing biliary hypertension. Soft tissue structure in the background of the presence of calculi in the gland tissue, distorting the head of the pancreas was regarded as a tumor, which was later confirmed by histological examination.

Table. 5 are the most common symptoms identified in CP and adenocarcinoma of the pancreatic head. The presence of a density gradient between the modified and unmodified tissue of pancreatic cancer in the absence of hypertension is more common for adenocarcinoma of the pancreatic head ( $p < 0,05$ ), while in CP is less pronounced or absent. Expansion of the main pancreatic duct may equally be observed in adenocarcinoma and CP, but the presence of calcifications and strictures that manifest change in diameter of GPP, rather points to the inflammatory nature of the disease.

Table 5

**The main differential diagnostic CT signs of chronic pancreatitis and adenocarcinoma of the pancreatic head**

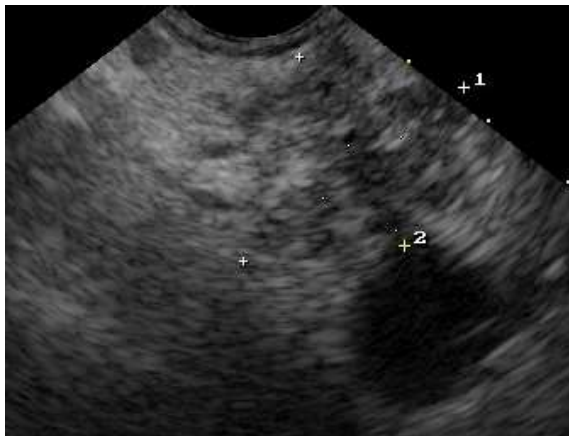
Symptoms	Adenocarcinoma n=146	Chronic pancreatitis n=171
Direct	Structure formation	calcinates
Indirect		
Expansion of the pancreatic duct		
-uniform	115 (87,7%)	13 (7,6%)
-uneven	3 (2,2%)	135 (78,9%)
The density gradient between the modified and unchanged tissue cancer in the arterial phase of the study (density, ed.N)		
-the expansion of GLP	62±8	64±12
-no extension of GLP	94±9	74±7
Portal hypertension	27 (20,6%)	93 (57%)
Biliary hypertension	117 (89,3%)	34 (19,8%)
-sharp narrowing of the diameter	103 (78,6%)	5 (2,9%)
-gradual narrowing of the diameter	15 (11,4%)	29 (16,9%)

EUS offers additional possibilities of differential diagnosis of pancreatic head tumors and pseudotumor pancreatitis. The sensitivity, specificity, and accuracy of EUS in the diagnosis of CP accounted for 80%, 86% and 84%, respectively. The

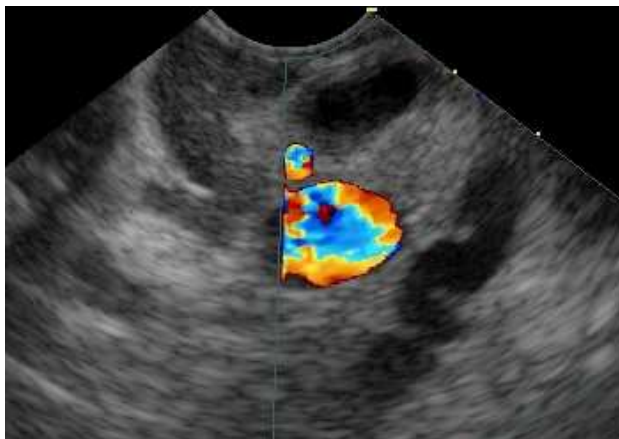
diagnosis of CP according to the EUS is based on a quantitative assessment of ultrasonographic criteria for pathological changes of GPP and pancreatic parenchyma.

CP signs are the following pathological changes (Fig. 2a, b, c):

- inhomogeneous eshostructural gland parenchyma, increased lobular (gain lobed structure - the lobules to 25mm);
- cysts (rounded anehogen structure 2mm more);
- expansion of GLP;
- tortuous course and irregular contour of GLP;
- hyperechoic duct wall;
- thickening and increased echogenicity of the wall of the GPP;
- intraductal echogenic formation with acoustic shadows and without them;
- presence of calcifications with acoustic shadows.

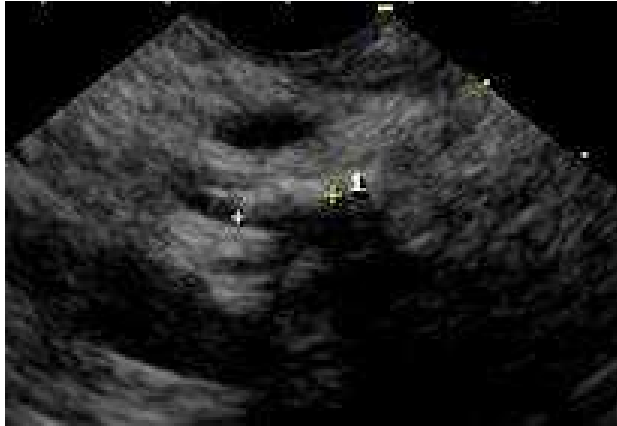

- 
- Fig. 2a



-

- Fig. 2b



- 
- Fig. 2c
- Fig. 2. Echographic picture of chronic pancreatitis
- a) Inhomogeneous echostructure of the pancreatic parenchyma, increased lobularity (increasing lobed structure — lobes up to 2–5 mm)
- b) Expansion of the main pancreatic duct for more than 3 mm in the pancreatic head, tortuous course and irregular contour
- c) Intraductal echogenic formations with acoustic shadows and without them

For pseudotumor pancreatitis is more common uniform hearth low echogenicity rounded shape with sharp edges. Pancreatic parenchyma were more often have lobular or lobed structure with increased echogenicity of the septum with a clear outline.

EUS allows visualization of tumors of small size (less than 3 cm). Usually they are homogeneous hypoechoic with a rounded shape, clear margins, distinguishable from the surrounding parenchyma (Fig. 3). Informative study repeatedly raises the possibility of fine-needle biopsy under ultrasound control with subsequent histological, cytological examination of the aspiration of the material (Fig. 4, 5).

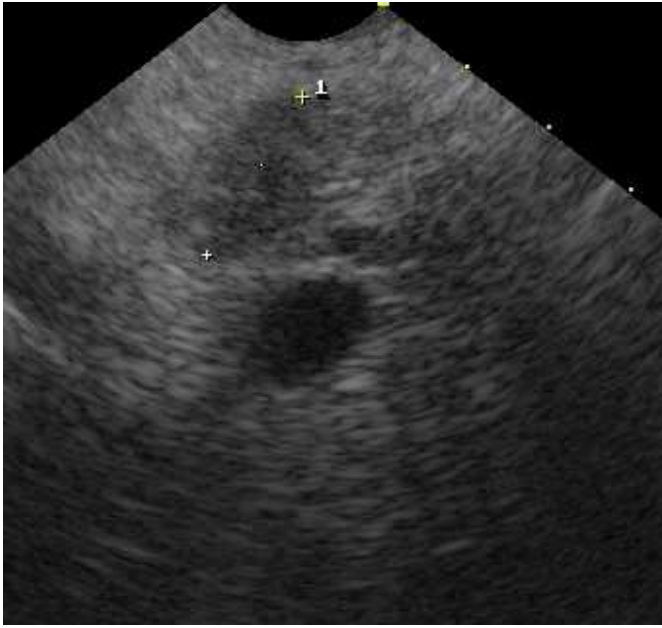


Fig. 3. Echographic picture of chronic pancreatitis

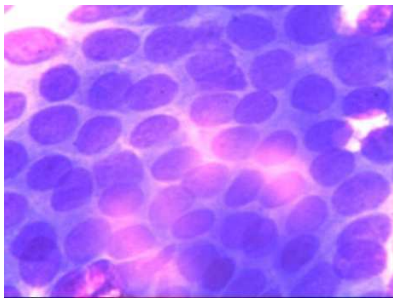


Fig. 4. Cytological picture of chronic pancreatitis

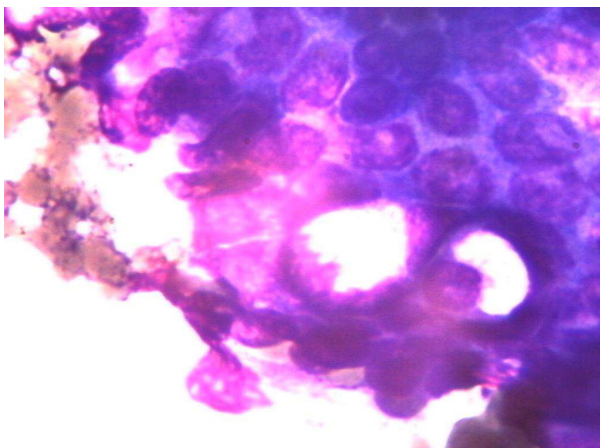


Fig. 5 Cytological picture of chronic pancreatitis

According to the literature, the sensitivity of EUS-TYPE reaches 80-90% specificity, and diagnostic accuracy - 90-95%. In this case, the negative predictive value was 55%, which does not exclude the presence of cancer of the data at negative biopsy.

In conclusion, it should be noted that the differential diagnostic criteria for cancer and KP are based on the presence of direct and indirect evidence. Direct CT sign of tumor formation is the presence of hypodense in the structure of the head glands to indirect signs include enlargement of the common bile duct with a sharp narrowing it to the level of education, uniform expansion of the main pancreatic duct, the combined expansion of both duct tumor in-growth of the great vessels, liver metastases. CP direct CT sign is the presence of calcifications in the structure of the gland tissue and in the pancreatic duct. Indirect signs of CP in the absence of calcifications are uneven expansion of the main pancreatic duct, and portal hypertension, biliary moderately severe hypertension. Action research is a highly sensitive method in the diagnosis of adenocarcinoma and chronic pancreatitis with a primary lesion of the pancreatic head. However, the final diagnosis should be carried out a comprehensive analysis of all laboratory and instrumental methods, including EUS with fine needle biopsy, in conjunction with the assessment of the clinical picture. EUS is a minimally invasive, effective and safe method for the diagnosis and differential diagnosis of pancreatic diseases. The method allows for fine-needle biopsy of education, histological and immunohistochemical study, which increases the diagnostic accuracy to 94%, and allows you to make a choice further treatment strategy.



## References

1. Диагностика и хирургическое лечение рака поджелудочной железы. / N. Hüser, V. Assfalg, D. Hartman [et al.] // Экспериментальная и клиническая гастроэнтерология. — 2011. — № 7. — С. 102–111.
2. Путов Н. В. Рак поджелудочной железы / Н. В. Путов, Н. Н. Артемьев, Н. Ю. Коханенко. — М. : Питер, 2005. — 396 с.
3. Рак поджелудочной железы: некоторые вопросы диагностики и лечения (сообщение 1) / А. П. Кошель, С. С. Клоков, Е. Б. Миронова, Н. В. Севастьянова // Вестник клуба панкреатологов. — 2010. — № 5. — С. 19–22.
4. Рак поджелудочной железы: некоторые вопросы диагностики и лечения (сообщение 2) / Г. К. Жерлов, А. П. Кошель, С. С. Клоков [и др.] // Вестник клуба панкреатологов. — 2010. — № 9. — С. 45–48.
5. Рекомендации Научного общества гастроэнтерологов России по диагностике и лечению хронического панкреатита (приняты 11 съездом НОГР 2 марта 2011 г. на заседании Российского панкреатического клуба) // Экспериментальная и клиническая гастроэнтерология. — 2011. — № 7. — С. 122–129.
6. Хронический псевдотуморозный панкреатит. Возможности дифференциальной лучевой диагностики / Г. Г. Кармазановский, В. А. Кубышкин, В. А. Вишневский [и др.] // Материалы I Конгресса Московских хирургов «Неотложная и специализированная помощь». Москва, 19–21 мая 2005 г. — М., 2005. — С. 300.
7. Bartosch-Härlid A. Diabetes mellitus in pancreatic cancer and the need for diagnosis of asymptomatic disease / A. Bartosch-Härlid, R. Andesson // Pancreatology. — 2010. — Vol. 10, No 4. — P. 423–428.
8. Catalano M. F. Diagnosis of chronic pancreatitis by endoscopic ultrasonography / M. F. Catalano, J. E. Geenen // Endoscopy. — 1998. — Vol. 30, Suppl. 1. — P. A111–115.

9. Chang K. J. State of the art lecture: endoscopic ultrasound (EUS) and FNA in pancreatico-biliary tumors / K. J. Chang // *Endoscopy*. — 2006. Vol. 38, Suppl. 1. — P. S56–60.
10. Detection of small pancreatic tumors with multiphasic helical CT / Y. L. Bronstein, E. M. Loyer, H. Kaur [et al.] // *AJR*. — 2004. — Vol. 182, No 3. — P. 619–623.
11. EUS-FNA mutation analysis in differentiating autoimmune pancreatitis and pancreatic cancer / A. Khalid, J. Dewitt, N. P. Otori [et al.] // *Pancreatology*. — 2011. — Vol. 11. — P. 482–486.
12. Frazee R. C. Endoscopic ultrasound for peripancreatic masses / R. C. Frazee, H. Singh, R. A. Erickson // *Am. J. Surg.* — 1997. — Vol. 174, No 6. — P. 596–598.
13. Hawes R. H. Indication for EUS-directed FNA / R. H. Hawes // *Endoscopy*. — 1998. — Vol. 30, Suppl. 1. — P. A155–157.
14. Krejs G. J. Pancreatic cancer: epidemiology and risk factors / G. J. Krejs // *Dig. Dis.* — 2010. — Vol. 28, No 2. — P. 355–358.
15. Levy M. J. Chronic pancreatitis focal pancreatitis or cancer? Is there a role for FNA/biopsy? / M. J. Levy, M. J. Wiersema, S. T. Chari // *Autoimmune pancreatitis*. — *Endoscopy*. — 2006. — Vol. 38. — P. S3–35.
16. Lilley M. The hereditary spectrum of pancreatic cancer: the Edmonton experience / M. Lilley, D. Gilchrist // *Can. J. Gastroenterol.* — 2004. — Vol. 18, No 1. — P. 17–21.
17. McKay C. J. Chronic inflammation and pancreatic cancer / C. J. McKay, P. Glen, D. C. McMillan // *Clinical Gastroenterology*. — 2008. — Vol. 22, No 1. — P. 65–73.
18. Pancreatic cancer in chronic pancreatitis: aetiology, incidence, and early detection / S. Raimondi, A. B. Lowenfels, A. M. Morselli-Labate [et al.] // *Clinical Gastroenterology*. — 2010. — Vol. 24, No 3. — P. 349–358.

19. Prospective evaluation of endoscopic ultrasonography and endoscopic cholangiopancreatography in patients with chronic abdominal pain of suspected pancreatic origin / M. J. Wiersema, R. N. Hawes, G. A. Lehman [et al.] // *Endoscopy*. — 1993. — Vol. 25. — P. 555–564.
20. A prospective pancreatographic study of the prevalence of pancreatic carcinoma in patients with diabetes mellitus / Y. Ogawa, M. Tanaka, K. Inoue [et al.] // *Cancer*. — 2002. — Vol. 94, No 9. — P. 2344–2349.
21. Small pancreatic lesions: is there need for EUS-FNA preoperatively? What to do with the incidental lesions? / H. Maguchi, K. Takahachi, M. Osanai [et al.] // *Endoscopy*. — 2006. — Vol. 38, Suppl. 1. — P. S148–152.
22. Small pancreatic lesions: is there need for EUS-FNA preoperatively? What to do with the incidental lesions? / H. Maguchi, K. Takahachi, M. Osanai [et al.] // *Endoscopy*. — 2006. — Vol. 38, Suppl. 1. — P. S148–152.
23. Suits J. Endoscopic ultrasound and fine needle aspiration for the evaluation of pancreatic masses / J. Suits, R. Frazee, R. A. Erickson // *Arch. Surg.* — 1999. — Vol. 134, No 6. — P. 639–642.
24. Ultrasonography, computed tomography and magnetic resonance imaging for diagnosis and determining resectability of pancreatic adenocarcinoma : a meta-analysis / S. Bipat, S. S. Phoa, O. M. van Delden [et al.] // *J. Comput. Assist. Tomogr.* — 2005. — Vol. 29, No 4. — P. 438–445.
25. Use of samples from endoscopic ultrasound-guided 19-gauge fine-needle aspiraton in diagnosis of autoimmune pancreatitis / T. Iwashita, I. Yasuda, S. Doi [et al.] // *Lincai Gastroenterology and Hepatology*. — 2012. — Vol. 3. — P. 316–322.

## **Chronic pancreatitis and pancreatic cancer**

L. B. Lazebnik<sup>1</sup>, L. V. Vinokurova<sup>1</sup>, N. I. Yashina<sup>2</sup>, E. V. Bystrovskaya<sup>1</sup>, D. S. Bordin<sup>1</sup>, E. A. Dubtsova<sup>1</sup>, Y. N. Orlova<sup>1</sup>

<sup>1</sup>*Central Research Institute of Gastroenterology,*

<sup>2</sup>*Institute of Surgery n. a. A. V. Vishnevsky of the Ministry of Health and Social Development, Moscow, Russia*

**Key words:** chronic pancreatitis, precancer, pancreatic cancer, computed tomography, endoscopic ultrasonography

Pancreatic cancer takes one of the leading places in the morbidity and mortality among the cancer of the digestive system. Article analyzes the possibilities of modern methods of diagnosis of pancreatic cancer and differential diagnostics of cancer and chronic pancreatitis: computed tomography and endoscopic ultrasonography. It is noted that computed tomography is a highly sensitive method of diagnosis of pancreatic cancer and chronic pancreatitis with a primary lesion of the pancreatic head. It is shown that verification of the diagnosis requires a comprehensive analysis of all laboratory and instrumental techniques, including endoscopic ultrasonography with fine-needle puncture and further cytological research.